

A LIGHT, TRANSMISSION AND SCANNING ELECTRON MICROSCOPE STUDY OF SNUFF-TREATED HAMSTER CHEEK POUCH EPITHELIUM

S.H. Ashrafi^{*,1,2}, A. Das¹, R. Worowongvasu¹, B. Mehdinejad², and J.P. Waterhouse¹

¹Department of Oral Medicine and Diagnostic Science and ²Department of Histology, Dental College, University of Illinois at Chicago, Chicago, IL 60680, U.S.A.

(Received for publication June 17, 1991, and in revised form February 5, 1992)

Abstract

The effects of smokeless tobacco (snuff) on hamster cheek mucosa were studied by light microscopy, transmission (TEM) and scanning electron microscopy (SEM). Two grams of commercially available smokeless tobacco were placed into the blind end of the right cheek pouch of each experimental animal, once a day and five days a week for 24 months. The control animals did not receive smokeless tobacco. After 24 months treatment with smokeless tobacco, hamster cheek mucosal epithelium lost its translucency and had become whitish in color. By light microscopy hyperorthokeratosis, prominent granular cell layers with increased keratohyalin granules and hyperplasia were seen. At the ultrastructural level, wider intercellular spaces filled with microvilli, numerous shorter desmosomes, many thin tonofilament bundles, increased number of mitochondria, membrane coating granules and keratohyalin granules were seen in snuff-treated epithelium. The changes in the surface of the epithelium as seen by SEM were the development of an irregular arrangement of the microridges and the disappearance of the normal honeycomb pattern. The microridges were irregular, widened and surrounded the irregular elongated pits. Some smooth areas without microridges and pits were also seen.

The long-term histological, TEM and SEM changes induced by smokeless tobacco treatment of the epithelium are well correlated with each other and were similar to those reported in human leukoplakia without dyskeratosis. They imply changes of pathological response resulting from topically applied snuff.

Key Words: snuff, hamster, oral epithelium, light microscopy, transmission electron microscopy, scanning electron microscopy, pre-cancerous lesion.

*Address for correspondence:

Shahid H. Ashrafi,

Dept. Oral Medicine and Diagnostic Sci. (M/C 838),
College of Dentistry, University of Illinois at Chicago,
801 South Paulina Street, Chicago, IL 60612.

Phone No.: (312) 996-8559

Introduction

The use of smokeless tobacco (chewing tobacco and snuff) is a common habit in several countries of the world and its use is on increase in the United States of America (Center for Disease Control, 1987; U.S. Department of Health and Human Services, 1990). Smokeless tobacco use has also been associated with oral mucosal lesions such as development of leukoplakia (Roed-Petersen and Pindborg, 1973; Axell *et al.*, 1976; Hirsch *et al.*, 1982; Poulson *et al.*, 1984; Giunta and Connolly, 1986; Holmstrup and Pindborg, 1988; Anderson *et al.*, 1989; Grady *et al.*, 1990), oral cancer (Christen, 1980; Winn *et al.*, 1981; Sundström *et al.*, 1982; McGuirt, 1983; Squier, 1984; Massey *et al.*, 1984; Schaefer *et al.*, 1985; Dandoy *et al.*, 1986; Jones and Pyper, 1986; Cullen *et al.*, 1986; Elzay, 1987; Winn, 1988; Gross *et al.*, 1988; Squier, 1988a, 1988b), gingival recession (Frithiof *et al.*, 1983; Christen and McDonald, 1987) tooth abrasion (Greer and Poulson, 1983) and effects on mucosal immune factors (Gregory *et al.*, 1991).

In particular, oral cancer is a major health concern, accounting for 3-4% of all cancers in the U.S. (American Cancer Society, 1988). Oral cancer has an overall five-year survival rate of about 51 percent (American Cancer Society, 1988). The patients who survive the disease may face significant cosmetic and functional impairment. The use of smokeless tobacco is increasing, especially among children and adolescent males (Squier 1988a, 1988b; Grady *et al.*, 1990, 1991; Schroeder *et al.*, 1991), and this may lead to an increased incidence of oral cancer in years to come.

We have reported that the daily application of snuff for six months to hamster cheek pouch mucosa produced hyperkeratosis (Worawongvasu *et al.*, 1991). The present study was under-taken to investigate the effects of snuff exposure for a prolonged period to oral epithelium. Therefore hamster cheek pouch mucosa was treated with snuff for twenty-four months to develop oral lesions and study their ultrastructural pathology.

Materials and Methods

Animals

Thirty-two male Syrian golden hamsters 12-14 weeks old were used in this study; 8 animals served as controls, the remaining 24 were used for experiments. Seven untreated controls and 22 experimental animals survived the experiment. Body weights ranged from 130-150 grams at the beginning of the experiment.

Test Procedures

Commercially available American manufactured moist snuff was used. Approximately two grams of snuff were placed into the blind end of the right buccal pouch of the experimental animals once a day, five days a week for 24 months. Nothing was placed into the pouches of the controls, but they were explored gently daily with the plastic cylinder of a syringe.

The animals were given laboratory chow (Agway Prolab Hamster 3000) and tap water *ad libitum*.

Tissue Preparation

At the end of the experiment the animals were sacrificed by ether inhalation. A 5 to 8 mm² piece of oral mucosa was excised from the blind end of each pouch. The tissue was further divided into several pieces for light and electron microscopy. A mixture of paraformaldehyde and glutaraldehyde containing a final concentration of 4% paraformaldehyde and 1% glutaraldehyde (Karnovsky, 1965) made in phosphate buffer (0.1 M) at pH 7.2 was used as the fixative for light microscopy, scanning electron microscopy and transmission electron microscopy.

The specimens for light microscopic study were fixed for 24 hours in the fixative, processed in an automated 18 hours processing cycle, and embedded in paraffin. Four blocks were prepared from each pouch and were stained with hematoxylin and eosin. The sections were viewed through a VISOPAN projection microscope (Reichert, Vienna, Austria) for counting and measuring the following:

1. Thickness of keratin layer (KE).
2. Thickness of nucleated epithelium (NE).
3. Thickness of KE + NE, and
4. Number of rows of cells in a nucleated layer.

The phrase: "thickness of keratin (KE)" means: thickness of keratin layer excluding the granular layer. "Thickness of nucleated epithelium (NE)" means: thickness of epithelium from junction between keratin layer and granular layer to the basement membrane. The phrase: "number of rows of cells in a nucleated layer" means: number of rows of nucleated epithelial cells from

granular layer to basal layer.

Each measurement was made directly on the image of the tissue on the screen of the VISOPAN projection microscope with a x63 objective. The system was calibrated using a projection of a micrometer scale, and values were finally expressed in μm .

For each parameter, measurements were made on 100 separate fields and means calculated. Grand mean values were then calculated and for purposes of simple analysis, differences analyzed by the two-tailed "t" test.

For transmission electron microscopy (TEM) studies, the tissues were trimmed into blocks of approximately 1 mm³ and fixed in the mixture of paraformaldehyde (4%) and glutaraldehyde (1%) in 0.1 M phosphate buffer (pH 7.2) at 4 °C for 2 hours. The fixed tissues were washed in 0.1 M phosphate buffer, pH 7.2, overnight and postfixed in 1% osmium tetroxide for 2 hours. Specimens were then dehydrated in ascending series of ethyl alcohol and propylene oxide. Tissues were embedded in Araldite. Ultra-thin sections 65-70 nm were cut, mounted on copper grids, stained with uranyl acetate and lead citrate. The stained sections were examined with a Philips 301A transmission electron microscope at 60 kV for observing ultrastructural features.

For the scanning electron microscopic (SEM) studies tissue were fixed for 2 hours and then transferred to phosphate buffer, pH 7.2, for washing overnight. They were dehydrated in ascending grades of ethanol and dried using a Denton critical point drying system. Tissues specimens were then mounted on aluminum stubs, coated with gold and examined for surface topography with a Cambridge Stereoscan S4-10 SEM operated at 20 kV with a tilt angle of 45 degrees.

Results

At the end of a 24-month experimental period, the gross examination of cheek pouch mucosa in the control group showed normal appearances while the mucosa of snuff-treated animals showed whitish patches. No tumors were observed.

Light Microscopy

Qualitative Findings: In control specimens the cheek pouch mucosa showed an orthokeratinized stratified squamous epithelium (Figure 1). The keratin layer was composed of acidophilic cells with indistinguishable cell outlines. There were 3-7 nucleated cell layers in the rest of the epithelium. The granular layer was indistinct; it contained small basophilic keratohyalin granules. There was no evidence of dysplasia. The junction between the basal cell layer and the lamina propria was generally without rete ridges however, small isolated areas showed one or two rete ridges.

Snuff-Treated Hamster Cheek Pouch Epithelium

Table 1. Mean Thickness of Nucleated (NE) and Keratin (KE) Layers of Hamster Buccal Pouch Epithelium and Mean Number of Cell Rows in the Nucleated Layers after 24 months of snuff treatment.

Animals	Thickness			Number of Epithelial Rows
	NE ($\mu\text{m} \pm \text{SEM}$)	KE ($\mu\text{m} \pm \text{SEM}$)	KE + NE ($\mu\text{m} \pm \text{SEM}$)	
Control	22.12 \pm 2.86	4.36 \pm 2.09	26.48 \pm 2.71	4.79 \pm 0.48
Experimental	29.22 \pm 1.82	13.29 \pm 2.06	42.50 \pm 3.77	7.14 \pm 0.35
% Increase Over Control	32.05*	204.82**	60.50*	48.85*

*Difference between means is statistically significant, $p < 0.05$

**Difference between means is highly significant, $p < 0.005$

The snuff-treated hamster cheek pouch also showed hyper-orthokeratinized stratified squamous epithelium (Figure 2). The keratin layer consisted of non-nucleated deeply acidophilic cells with more distinguishable cell borders than in 24-month controls. There were 5-12 nucleated epithelial cell layers in the rest of the epithelium. The granular cell layer was more prominent than that of the control group. The lamina propria consisted of dense fibrous tissue with some inflammation.

Quantitative Findings

After 24-months of snuff administration, the keratinized (KE) and nucleated layers (NE) of the pouch mucosa of experimental animals were thicker than those of control animals (Table 1). The thickness of the epithelial layer comprising KE + NE of the 24-month treated group was increased by 60.50% compared to the controls, and the difference was significant ($p < 0.05$). The NE of the experimental group after 24 months was increased by 32.05% (difference significant, $p < 0.05$, Table 1) than that of the controls. The KE of the treated hamsters after 24 months was increased by 204.82% (difference significance $p < 0.005$; Table 1) compared to controls. The number of rows of cells in the experimental group was 48.85% greater (difference significance $p < 0.05$) than in the controls after 24 months (Table 1).

Transmission Electron Microscopic Observations

Control Group. The stratified squamous epithelium of the hamster cheek pouch consisted of basal lamina, basal cell, spinous cell, granular cell and keratinized cell layers (Figure 3). The epithelial cells

were intact and stratum corneum consisted of 4-6 fully keratinized compact layers. The basal cells were bounded by a continuous basal lamina zone. Lamina lucida and lamina densa were parallel to the plasma membrane of the basal cells (Figure 4) and separated the underlying connective tissue from basal cells. The basal cells consisted of nuclei with aggregates of prominent heterochromatin associated with a nucleolus. A few profiles of rough endoplasmic reticulum were seen. The cytoplasmic ribosomes in the form of polyribosomes were distributed throughout the cell. Several mitochondria and thick bundles of tonofilaments were seen throughout the cell. Narrow intercellular spaces between cells were present. The desmosomes were well developed and tonofilaments were attached to the desmosomal attachment plaque. Occasionally non-keratinocytes in basal cell layers were seen. The spinous cell layer consisted of 2-3 cell layers. The nuclear-to-cytoplasmic ratio in spinous cells was lower than in basal cells. Heterochromatin was not prominent, tonofilament bundles became shorter, and mitochondria and many membrane coating granules (MCGs) were present (Figure 5). The granular cell layers consisted of 2-3 layers with elongated nuclei. A few mitochondria and several MCGs were seen. Elongated or circular keratohyalin granules (KHGs) were present (Figure 5). The tonofilament bundles and desmosomes were shorter. The MCGs were observed to discharge their content into intercellular spaces of the outermost granular cell layer lying adjacent to the first keratinized cell layer.

The keratinized epithelial cell layer was orthokeratinized with electron dense layers due to embedded tonofilaments. In the first keratin layer, the cells in

transition showed nuclear profiles and KHGs. The intercellular spaces were prominent. Intracellular vacuoles, empty or containing debris, were also observed.

Snuff-Treated Group. The epithelium of the snuff treated hamster cheek pouch showed wider intercellular spaces with patchy electron dense material present in them, (Figure 6). The basal cells showed a few dilated rough endoplasmic reticulum and shorter desmosomes with narrow attachment plates. The tonofilament bundles were thin. Less heterochromatin and more euchromatin were seen. The widened intercellular spaces were filled with microvilli projecting from plasma membranes. The plasma membrane of basal cells projected into the connective tissue zone (Figure 6). At a very few places duplication of basement membrane was seen. The spinous cells showed widened intercellular spaces and shorter desmosomes with thin tonofilament bundles. The number of mitochondria and MCGs in these cells was increased (Figure 7). The granular cells showed more KHGs and MCGs (Figure 8) than controls. A few MCGs extruded their contents into the intercellular spaces by comparison with controls, and the number of tonofilament bundles was also increased.

The number of KHGs was increased with the number of granular cell layers. The early keratinized cell layers were less electron dense. Some of them still contained cytoplasmic organelles especially KHGs and degenerated nuclei were clearly visible.

A mild inflammatory cell reaction in the connective tissue region was noticed. Several macrophage components were aligned near the basal lamina in the connective tissue (Figure 6). Intraepithelial non-keratinocytes were observed in basal and first suprabasal spinous cell layers.

Scanning Electron Microscopic Observations

The surface of the control cheek mucosa at low magnification was somewhat irregular and roughened (Figure 9); few desquamating cells were seen. At medium magnification a honeycomb pattern of pits surrounded by macroridges, was still discernible. The prominent intercellular microridges separating cells were present (Figure 10). In some areas, the surface was still undulated. The surface of the individual cells showed depressions surrounded by short wavy microridges.

The experimental cheek mucosa at low magnification showed deep fissures separated by smooth-appearing aggregates of squames (Figure 11). The overall surface was smooth and lobulated. At medium magnification, fissures were clearly seen (Figure 12). The surface was irregular. The microridges and the pits were irregular. The macroridges separating cells were not visible. The

Fig 1. Histological section of hamster buccal mucosa from a control animal showing nucleated epithelium (NE) and keratinized epithelium (KE). Bar = 20 μ m.

Fig 2. Histological section of hamster buccal mucosa from snuff treated animal showing increase in thickness of NE and KE. Bar = 20 μ m.

Fig 3. Transmission electron micrograph of control stratified squamous epithelium of hamster cheek pouch mucosa. Lamina propria (LP), basal lamina (BL), basal cell (BC), spinous cell (SC), granular cell (GC) and keratinized cell (KE) layers are seen. Bar = 2 μ m.

Fig 4. Electron micrograph of basal cell region and lamina propria of control hamster cheek pouch mucosa. The basal lamina (BL) region shows hemidesmosomes (HD) and the lamina densa (LD) and the lamina lucida (LL). Bundles of collagen fibrils are present in the lamina propria region. Note polyribosomes (PR), mitochondria (MT) and tonofilament bundles (TF), large nucleus (N) with heterochromatin, narrow intercellular spaces (ICS) and desmosomes (D). Bar = 1 μ m.

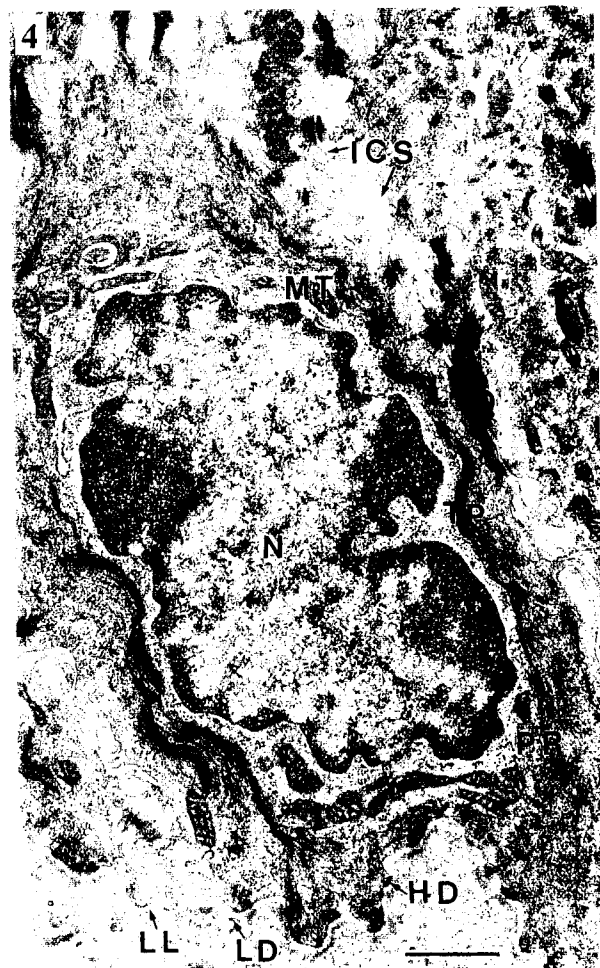
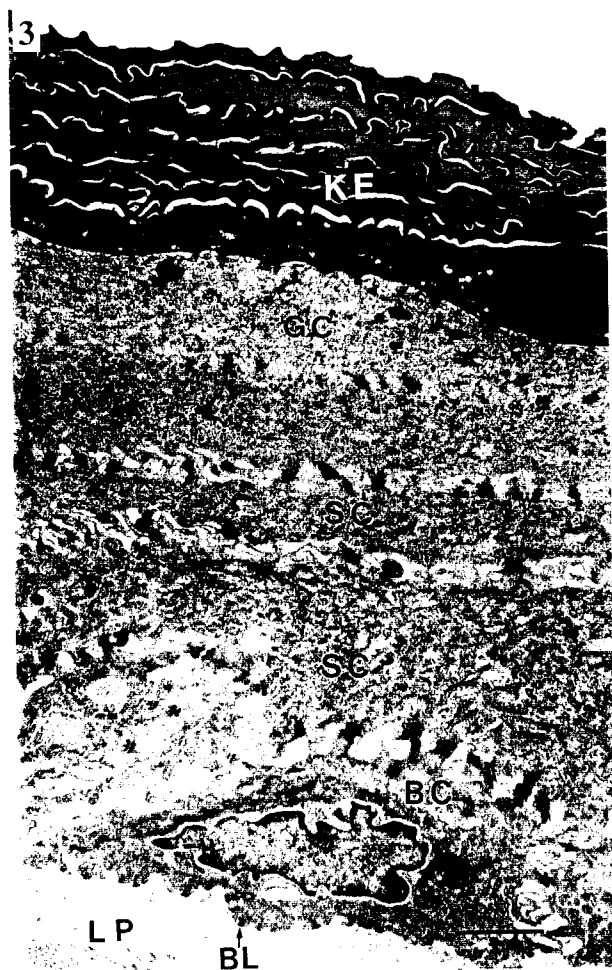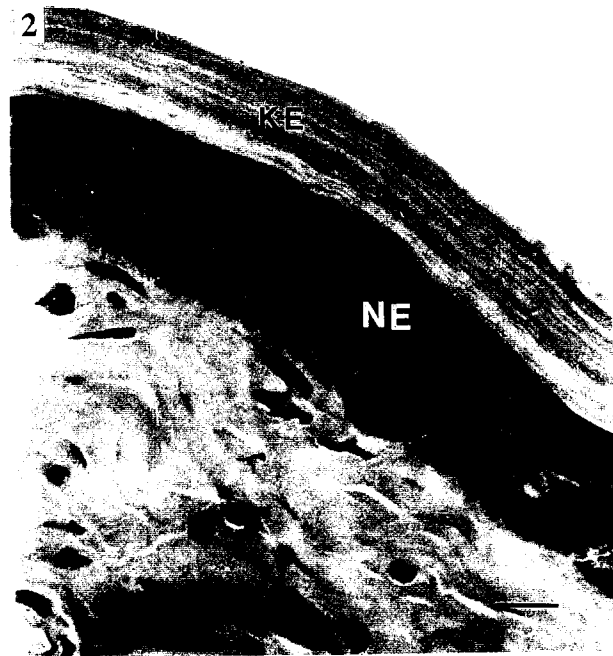
honeycomb appearance of the surface was still visible in some areas. Smooth areas with irregular microridges were clearly seen. At higher magnification, the microridges were elongated and irregular. The depressions were shallow, irregular or absent (Figure 13).

Discussion

In the present study, hamster cheek pouch was used. This model system is reliable since oral cancer has consistently been induced experimentally (Shklar *et al.*, 1979; Gijare *et al.*, 1989). This model has also been successfully used for the study of oral mucosal premalignancy and malignancy (White and Gohari, 1984; Hassanin *et al.*, 1987; Hassanin and Ashrafi, 1988; Kandarkar *et al.*, 1991). In the present study mild epithelial hyperplasia was also noticed in control animals. However, in the experimental animals the thickness of the keratin layer (KE), and of the nucleated epithelial cell layers (NE) and the combined thickness of the KE and NE were significantly increased after 24 months of the snuff treatment.

The thickening of the KE layer accounted for the white appearance of mucosa. The thickening of the NE layer was due to hyperplasia rather than to hypertrophy of the keratinocytes. Hirsch and Thilander (1981) and Hirsch and Johansson (1983), using snuff in rats, found similar results after 22 months of experiment. One or two rete ridges seen in isolated areas of normal mucosa were also observed by McMillan and Kerr (1990) in normal hamster cheek mucosa. However, the number of basal cell processes extended into the connective tissue was increased in snuff-treated animal tissues.

Snuff-Treated Hamster Cheek Pouch Epithelium



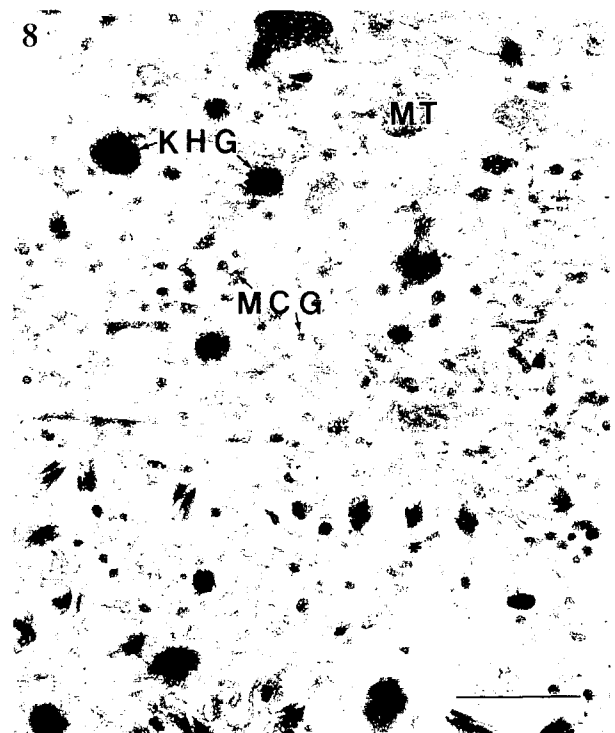
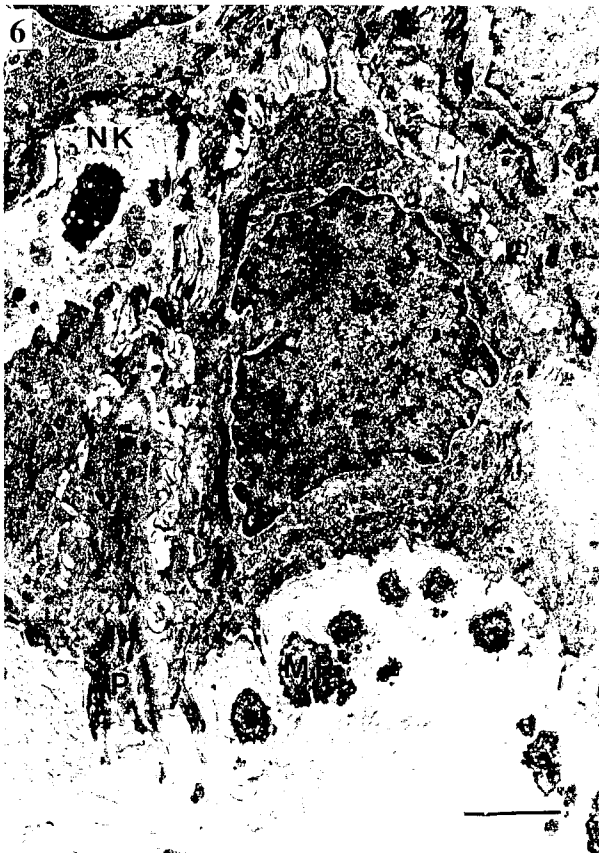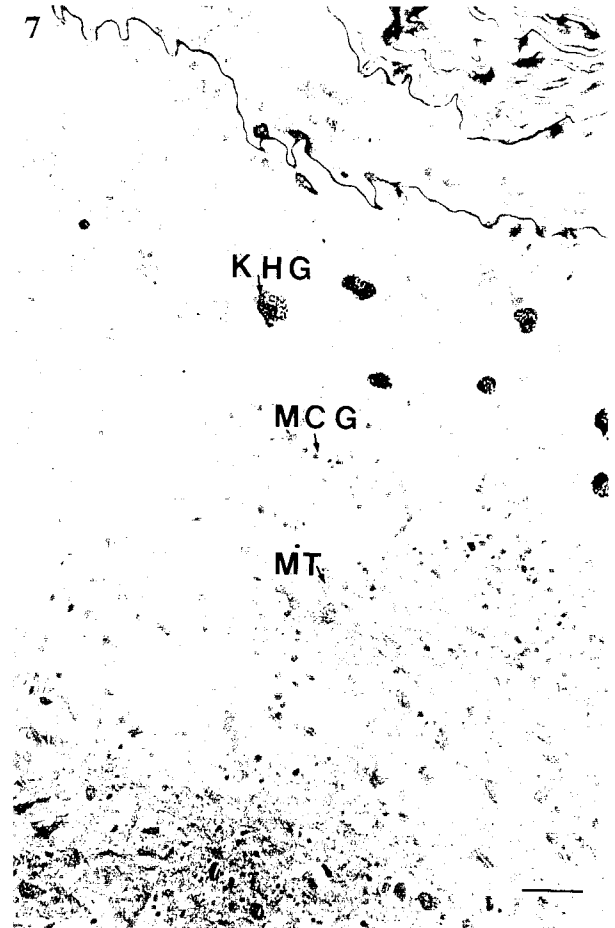
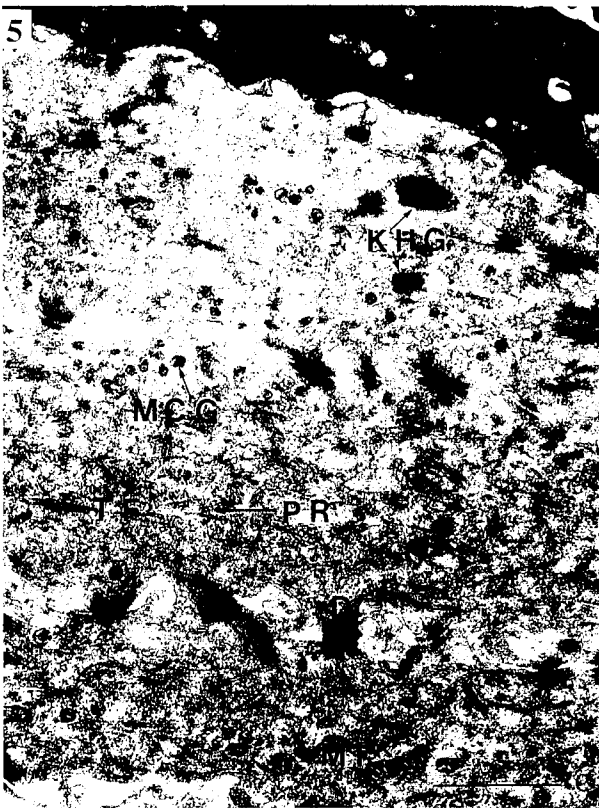


Fig. 5. Electron micrograph from control showing few mitochondria (MT), membrane coating granules (MCG), desmosomes (D), tonofilament bundles (TF) and polyribosomes (PR) in spinous and granular cell layers. Keratohyalin granules (KHG) are also present in granular cells. Bar = 1 μ m.

Fig. 6. Basal cell (BC) from snuff-treated animal showing wider intercellular spaces filled with microvilli like projections. Basal cell processes extending into the connective tissue (P), macrophage components, (MP) close to the basal lamina, and intraepithelial non-keratinocytes (NK) are present. Bar = 2 μ m.

Fig. 7. Electron micrograph from experimental animal showing spinous cell, granular cell and orthokeratinized cell layers. Note more MT, MCGs and KHGs are retained in nucleated layers than in controls. Degenerated KHGs are present in less electron dense keratinized cells. Bar = 1 μ m.

Fig. 8. Experimental epithelium showing numerous MCGs in granular cell. KHGs and MT are also present. Bar = 1 μ m.

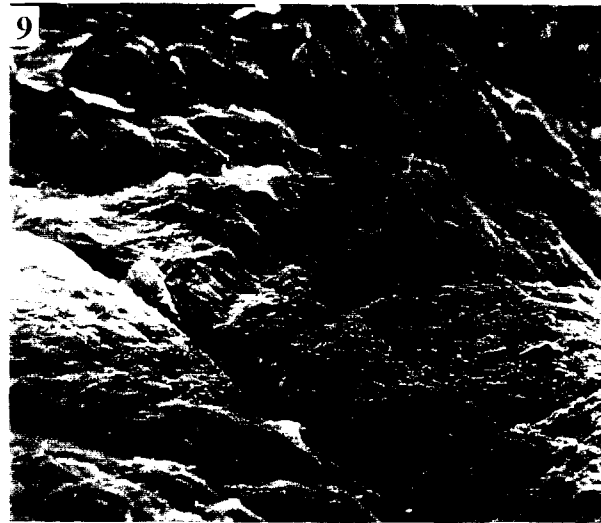
Fig. 9. A scanning electron micrograph of control hamster cheek epithelium showing an irregular and roughened surface with few desquamating cells (arrows). Bar = 40 μ m.

Fig. 10. At a higher magnification the surface of the control epithelium with distinct margins of individual squames, is seen. Macroridges are seen at the margins of the squames (arrow heads) and pits in these cell surface are surrounded by microridges (arrows) forming a honeycomb appearance. Bar = 10 μ m.

Fig. 11. The surface of the snuff-treated epithelium shows a pattern of deep fissures separated by smooth-surfaced aggregates of squames. Bar = 40 μ m.

The ultrastructural changes noticed in hamster cheek pouch epithelium were similar to those found by Banoczy *et al.* (1980) in human leukoplakia simplex. The widening of intercellular spaces in smokeless tobacco treated hamster cheek pouch epithelium is similar to that reported by others for leukoplakic lesions developed in response to carcinogens in hamster cheek pouch (Listgärten *et al.*, 1963; Hassanin and Ashrafi, 1988; Kandarkar *et al.*, 1991) and in human snuff-treated lesions (Frithiof *et al.*, 1983; Jungel and Malmström, 1985).

This may be due to inflammation and a reduction in calcium concentration necessary for cellular growth (Menon and Elias, 1991) and cell adhesion (Hennings



and Holbrook, 1983). Nuclei in snuff-treated epithelial cells appeared to be similar to those in controls. An increase in the number of membrane coating granules over control cells was noticed. Similar results have been reported by others (Hayward, 1979; Hassanin and Ashrafi, 1988; Frithiof *et al.*, 1983; Jungel and Malmström, 1985; Kandarkar *et al.*, 1991). Hashimoto and Lever (1966) observed abnormally large numbers of MCGs in psoriatic epidermis and Ashrafi *et al.* (1980) reported increased numbers of MCGs in the hyperplastic oral epithelium of zinc deficient rats. The increased numbers of MCGs in snuff-treated pouch epithelium or in other cases of hyperplastic epithelium may be due to an accumulation of them because of the failure of the process whereby the contents of MCGs are extruded into intercellular spaces (Ashrafi *et al.*, 1980; Madison *et al.*, 1988; Dale *et al.*, 1990). Thus number of MCGs is increased. This may create a defective permeability barrier because the permeability barrier in epithelium is laid down with the discharge of contents of granules into the intercellular spaces (Squier, 1973; Elias and Friend, 1975). So far we have no information on how the changes in number and position of MCG in smokeless tobacco treated epithelium described here might influence the permeability of this tissue. As hyperplasia is invariably a component of the epithelial changes that precede overt invasiveness, the behavior of membrane coating granules in hyperplasia may well deserve a further study.

Pseudopodia-like projections of basal cells seen in smokeless tobacco treated epithelium were also noticed in chemically induced precancerous lesions (Kendrik, 1964; Shklar *et al.*, 1985; Woods and Smith, 1970; Hassanin and Ashrafi, 1988; Kandarkar *et al.*, 1991). The cytoplasmic basal cell processes extending into connective tissue have also been reported (Frithiof *et al.*, 1983; Jungel and Malmström, 1985). The dilated profiles of endoplasmic reticulum and lymphatic proliferation seen in experimental epithelial cells were also noticed in hamster cheek pouch epithelium treated with carcinogen (White and Gohari, 1984; Kandarkar *et al.*, 1991).

Scanning electron microscopic examination showed surface topographic changes on the cheek epithelium of the experimental animals (Table 2). Irregular and widened microridges surrounding irregular pits were developed. Similar changes in 2-week DMBA (dimethyl-1-2-benzanthracene) treatment of the hamster cheek pouch were reported (Hassanin *et al.*, 1987; Hassanin and Ashrafi, 1988). The honeycomb surface pattern of keratinized epithelium as seen in control disappeared from some areas of snuff-treated cheek pouch epithelium. Smooth areas without microridges and pits were clearly seen in treated animals. In some areas, low irregular microridges could be seen. Similar changes after six-month snuff treatment of hamster cheek pouch epithelium were also reported (Chomette *et al.*, 1981; Worawongvasu *et al.*, 1991). The surface morphology was similar to the surface structure of lesion of

leukoplakia without dysplasia in human buccal epithelium (Reichart and Althoff, 1983; Banoczy *et al.*, 1980), and the surface pattern of the epithelium of oral lichen planus, reticular type, without dysplasia (Jungell *et al.*, 1987).

The changes in the keratinization pattern of keratinized cells shown by TEM and SEM in snuff-treated epithelium were correlated. These findings were supported by the studies of Reichart and Althoff (1979), Banoczy *et al.* (1980), Jungell *et al.* (1987) and Hassanin and Ashrafi (1988).

The present study confirms specific differences between the normal and snuff-treated hamster cheek pouch epithelium. Based on these findings we conclude that oral epithelial changes found in this study were associated with direct chemical effects of topically applied snuff.

Acknowledgements

We are indebted to Dr. Stanley Gerson, Acting Head, Department of Oral Medicine and Diagnostic Sciences for Departmental support and scientific consultation during the progress of the study. We would like to thank Minu Patel, Assistant Professor, Biostatistics Facility, University of Illinois at Chicago for his help in statistical analysis of the data. We further acknowledge the technical assistance of Eugenia Kraucunas and Elena Baltrusaitis in electron microscopy, Isabel Stancius in printing and Farris Williams in typing the manuscript. This study was supported in part by Wach Fund, University of Illinois at Chicago, 2-6-46586.

References

- American Cancer Society (1988) Cancer facts and figures, New York.
- Anderson D, Axell T, Larsson A (1989). Histological changes associated with the use of loose and portion-bag packed Swedish moist snuff: a comparative study. *J Oral Pathol Med* **18**: 491-497.
- Ashrafi SH, Meyer J, Squier CA (1980). Effects of zinc deficiency on the distribution of membrane coating granules in rat buccal epithelium. *J Invest Dermatol* **74**: 425-432.
- Axell T, Mörnstad H, Sundström B (1976). The relation of the clinical picture to the histopathology of snuff dipper's lesions in a Swedish population. *J Oral Pathol* **5**: 229-236.
- Banoczy J, Lapis K, Albrecht M (1980). Scanning electron microscopic study of oral leukoplakia. *J Oral Pathol* **9**: 145-154.
- Center for Disease Control (1987). Smokeless tobacco use in the United States: Behavioral risk factor surveillance system. *Morbidity and Mortality Weekly Report* **36**: 337-340.
- Christen AG (1980). The case against smokeless tobacco: five facts for the health professional to consider. *J.A.D.A.* **101**: 464-469.




Fig. 12. At a medium magnification this scanning micrograph shows fissures separated by undulating areas of squames. Indistinct cell margins and irregular patterns of pits are surrounded by microridges (arrows). Bar = 10 μ m.

Fig. 13. At a higher magnification the surface of individual squames of the snuff-treated epithelium shows some pits or depressions surrounded by microridges (arrows). Numerous elongated microridges are also seen. Bar = 4 μ m.

Table 2. SEM comparison between control and experimental surface changes of hamster buccal pouch mucosae.

	Low Magnification	High Magnification
Control	Irregular and roughened surface with some deeper clefts. No gentle folds, a few desquamating cells.	Honeycomb appearance in some areas and depressions surrounded by short wavy microridges in other areas.
Experimental	Lobulated surface with deep fissures, no gentle folds.	Honeycomb appearance in a very few areas. Irregular and elongated microridges surrounding elongated pits. Moderate numbers of smooth areas without microridges.

Christen AG, McDonald Jr. JL (1987). Smokeless tobacco country: from nicotine dependency to oral problems and cancer. *Aviat Space Environ Med* **58**: 97-104.

Cullen JW, Blot W, Henningfield J, Boyd G, Mecklenburg R, Massey MM (1986). Health consequences of using smokeless tobacco: Summary of the Advisory Committee's Report to the Surgeon General. *Public Health Rep* **101**: 355-373.

Chomette G, Leclerc JP, Szpirglas H, Auriol M, Vaillant JM (1981). Scanning electron microscopy of normal malignant and post radiotherapeutic oral mucosal cells. *Pathol Res Pract* **171**: 345-352.

Dale BA, Holbrook KA, Fleckman P, Kimball JR, Brumbaugh S, Sybert VP (1990). Heterogeneity in harlequin ichthyosis, an inborn error of epidermal keratinization: Variable morphology and structural protein expression and a defect in lamellar granules. *J Invest Dermatol* **94**: 6-18.

Dandoy S, Edwards G, Lindsay G (1986). Smokeless tobacco: An overview for physicians. *West J Med* **145**: 111-113.

Elias PM, Friend DS (1975) The permeability barrier in mammalian epidermis. *J. Cell Biol.* **65**: 185-191.

Elzay RP (1987). Oral cancer and smokeless tobacco. *Virginia Med* **14**: 84-90.

Frithiof L, Anneroth G, Lason U, Sederholm C (1983). The snuff-induced lesion. A clinical and morphological study of a Swedish material. *Acta Odontol Scand* **41**: 53-64.

Gijare PS, Rao KVK, Kandarkar SV, Borges AE, Bhide SV (1989). Sequential analysis of experimental oral carcinogenesis in hamster cheek pouch using 9,10-dimethyl-1-2-benzanthracene. *Indian J Exp Biol* **27**: 685-691.

Giunta JL, Connolly G (1986). The reversibility

- of leukoplakia caused by smokeless tobacco. *J.A.D.A.* **113**: 50-52.
- Grady D, Greene J, Daniels TE, Ernster VL, Robertson PB, Hauck W, Greenspan D, Greenspan J, Silverman S (1990). Oral mucosal lesions found in smokeless tobacco users. *J.A.D.A.* **121**: 117-123.
- Grady D, Green J, Ernster VL, Daniel TE, Stillman L, Silverman S (1991). Short term changes a surprise with smokeless tobacco oral lesions **122**: 62-64.
- Greer RO, Poulson TC (1983). Oral tissue alterations associated with the use of smokeless tobacco by teenagers. Part I. Clinical findings. *Oral Surg Oral Med Oral Pathol* **56**: 275-284.
- Gregory RL, Kindle JC, Hobbs LC, Sing-Jairan M, Malonstrom HS (1991). Immunobiological effects of smokeless tobacco: secretory IgA structure/function. First International Conference on Smokeless Tobacco: Tobacco and Health, Columbus, Ohio (Abstract 4), Available from Dept. Conferences, OSU, Columbus, OH 43210.
- Gross JY, D'Alessandri R, Powell VL, Rodeheaver A (1988). Smokeless tobacco: health hazard on the rise. *South Med J* **81**: 1089-1091.
- Hashimoto K, Lever WF (1966). Elektronenmikroskopische Untersuchungen der Hautveränderungen bei Psoriasis (Ultrastructural investigations on skin changes in psoriasis). *Dermatol Wochenschr* **152**: 713-722.
- Hassanin MB, Ashrafi SH, Das AK (1987). Surface ultrastructural changes in chemically induced premalignant lesions in the hamster cheek pouch. *J Oral Pathol* **6**: 273-277.
- Hassanin MB, Ashrafi SH (1988). Comparative light scanning and transmission electron microscopic study of chemically induced premalignant lesions in hamster's cheek pouch. *Ultrastruc Pathol* **12**: 341-350.
- Hayward AF (1979). Membrane coating granules. *Int Rev Cytol* **59**: 97-127.
- Hennings H, Holbrook KA (1983). Calcium regulation of cell-cell contact of differentiation of epidermal cells in culture: an ultrastructural study. *Exp Cell Res* **143**: 127-142.
- Hirsch JM, Thilander H (1981). Snuff-induced lesions of the oral mucosa. An experimental model in the rat. *J Oral Pathol* **10**: 342-353.
- Hirsch JM, Heyden G, Thilander H (1982). A clinical, histomorphological and histochemical study of snuff-induced lesions of varying severity. *J Oral Pathol* **11**: 387-398.
- Hirsch JM, Johansson SL (1983). Effect of long-term application of snuff on the rat mucosa: An experimental study in the rat. *J Oral Pathol* **12**: 187-198.
- Holmstrup P, Pindborg JJ (1988). Oral mucosal lesions in smokeless tobacco users. *Ca: A Cancer Journal for Clinicians* **38**: 230-235.
- Jones RB, Pyper SA (1986). Smokeless tobacco: a public health challenge. *Wis Med J* **85**: 14-17.
- Jungell P, Malmström M (1985). Snuff-induced lesions in Finish recruits. *Scand J. Dent. Res.* **93**: 442-447.
- Jungell P, Malmström M, Wartiovaara J, Kontinen Y (1987). Ultrastructure of oral leukoplakia, lichen planus. II. A correlated scanning and transmission electron microscopic study of epithelial surface cells. *J Oral Pathol* **16**: 287-293.
- Kandarkar SV, Gijare PS, Rao KVK, Bhide SV (1991). Electron microscopic changes on the DMBA induced oral precancerous and cancerous lesion in hamster cheek pouch. *Cell Biol Intern Reports* **15**: 107-119.
- Karnovsky MJ (1965). A formaldehyde-glutaraldehyde fixative of high osmolarity for use in electron microscopy. *J Cell Biol* **27**: 137a.
- Kendrik FJ (1964). Some effect of a chemical carcinogen and a cigarette smoke condensate upon hamster cheek pouch mucosa. *Health Sciences* **24**: 3698-3699.
- Listgärten MA, Albright JT, Goldhaber P (1963). Ultrastructural alterations in hamster cheek pouch epithelium in response to a carcinogen. *Archives of Oral Biology* **8**: 145-165.
- Madison, KC, Swartzendruber DC, Wetz PW, Downing DT (1988). Lamellar granule extrusion and stratum corneum intercellular lamellae in murine keratinocyte cultures. *J Invest Dermatol* **90**: 110-116.
- Massey Jr. JD, Moore GF, Yonkers AJ (1984). Smokeless tobacco: a risk factor in oral cancer. *Ear Nose Throat J* **63**: 453-458.
- McGuirt WF (1983). Snuff dipper's carcinoma. *Arch Otolaryngol* **109**: 757-760.
- McMillan MD, Kerr MA (1990). A light and scanning electron microscope study of epithelial thickenings and rete ridges in the adult hamster cheek pouch. *Archs Oral Biol* **35**: 235-240.
- Menon GK, Elias PM (1991). Ultrastructural localization of calcium in psoriatic and normal human epidermis. *Arch Dermatol* **127**: 57-63.
- Poulson TC, Lindenmuth JE, Greer RO (1984) A comparison of the use of smokeless tobacco in rural and urban teenagers. *Ca: A Cancer Journal for Clinicians* **34**: 248-261.
- Reichert PA, Althoff J (1983). A scanning electron microscopic study of epithelial surface patterns. *Int J Oral Surg* **12**: 159-164.
- Roed-Petersen B, Pindborg JJ (1973). A study of Danish snuff-induced oral leukoplakias. *J Oral Pathol* **2**: 301-313.
- Schaefer SD, Henderson AH, Glover ED, Christen AG (1985). Patterns of use and incidence of smokeless tobacco consumption in school-age children. *Arch Otolaryngol* **111**: 639-642.
- Schroeder KL, Tofil PJ, Dupler J (1991). Survey of tobacco usage and initiations among rural elementary school children: Implications for prevention programs. First International Conference on Smokeless Tobacco: Tobacco and Health, Columbus, Ohio (Abstract 49), Available from Dept. Conferences, OSU, Columbus, OH 43210.
- Shklar G, Eisenberg E, Flynn E (1979). Immuno-

enhancing agents and experimental leukoplakia and carcinoma of the hamster buccal pouch. *Prog Exp Tumor Res* 24: 269-282.

Shklar G, Niukian K, Hassan M, Herbosa EG (1985). Effects of smokeless tobacco and snuff on oral mucosa of experimental animals. *J Oral Maxillofac Surg* 43: 80-86.

Squier CA (1973) The permeability of keratinized and non-keratinized oral epithelium to horseradish peroxidase. *J Ultrastruct Res* 43: 60-77.

Squier CA (1984). Smokeless tobacco and oral cancer: a cause for concern. *Ca: A Cancer Journal for Clinicians* 34: 242-247.

Squier CA (1988a). Introduction: proceedings of a symposium on the health effects of smokeless tobacco. *Ca: A Cancer Journal for Clinicians* 38: 224-225.

Squier CA (1988b). The nature of smokeless tobacco and patterns of use. *Ca: A Cancer Journal for Clinicians* 38: 226-229.

Sundström B, Mörnstad H, Axell T (1982). Oral carcinomas associated with snuff dipping. Some clinical and histological characteristics of 23 tumors in Swedish males. *J Oral Pathol* 11: 245-251.

U.S. Department of Health and Human Service (1990). Smoking, Tobacco, and Cancer Program. 1985-1989 Status Report. N.I.H. Publication No. 90-3107: 12-46 (Available from National Institutes of Health, Bethesda, MD).

White H, Gohari K (1984). A qualitative ultrastructural study of the intercellular spaces between epithelial cells treated in vivo with DMBA. *J Oral Path* 13: 231-234.

Winn DM, Blot WJ, Shy Cm, Pickle LW, Toledo A, Fraumeni JF (1981). Snuff dipping and oral cancer among women in the southern United States. *New Eng J Med* 304: 745-749.

Winn DM (1988). Smokeless tobacco and cancer: The epidemiologic evidence. *Ca: A Cancer Journal for Clinicians* 38: 236-243.

Woods DA, Smith CJ (1970). Ultrastructure and development of epithelial cell pseudopodia in chemically induced premalignant lesions of the hamster cheek pouch. *Exp Mol Pathol* 12: 160-174.

Worawongvasu R, Ashrafi SH, Das AK, Waterhouse JP (1991). A light and scanning electron microscopic study of snuff induced early changes in hamster cheek pouch mucosa. *Biomed Res* 2: 240-250.

Discussion with Reviewers

Reviewer I: Is hamster cheek pouch a suitable model for snuff carcinogenesis? Is it appropriate to compare the observed changes with those brought about by known carcinogens, such as DMBA?

Authors: Based on our studies it is difficult to say yes or no. Moreover, snuff commercially available in the USA, contains carcinogenic tobacco specific nitrosamines including N'-nitrosornicotine (NNN) and 4-(menthyl nitrosamino)-1-(3-pyridyl)-1-butanone (NNK)

which are strong carcinogens in mice, rats and hamsters, (Hecht SS, Rivenson A, Braley J, Dibollo J, Adams JD, Hoffmann D, 1986. Induction of oral cavity tumors in F 344 rats by tobacco-specific nitrosamines and snuff. *Cancer Res* 46: 4162-4166). However, two years snuff exposure did not produce tumor in the cheek pouch epithelium. The aim of this study was not to produce carcinoma, but to study the effects of snuff on the ultrastructure of the epithelium after two years exposure. Since hamsters have been used by majority of researchers to investigate the effects of known chemical carcinogens on the ultrastructure of the cheek pouch epithelium, therefore it was easier to compare our results by using the same animal in our study.

Reviewer I: Do you think that changes reported represented extended mechanical and/or chemical irritation?

Reviewer II: Should there have been a control group in which inactive ingredients (i.e., no carcinogens) were placed in cheek pouches to observe the effects of simple chronic irritation?

Authors: In previous studies wood powder was used to pack the pouch and precancerous lesions were not observed like those seen in snuff-treated epithelium. Therefore, the changes seen could not be mechanical.

Reviewer I: How was the thickness determined so as to allow for the irregularities of the basement membrane and surface?

Authors: The basement membrane of a hamster cheek pouch epithelium is not irregular as in the case in many other epithelia. However, to avoid problems with the use of surface length, a line was drawn on a projected drawing to approximate the linear surface covered by the epithelial section being examined, uninfluenced by the system of epithelial irregularities.

Reviewer I: Why are measurements made of the parameters that show a distinct alteration (epithelial and keratin thickness) when changes in numbers of organelles (that are far harder to evaluate subjectively were not measured)?

Authors: Sometime distinct alteration may not reach statistical significance. Therefore, epithelial and keratin thickness were measured and statistically analyzed to show the differences. Measurements to show the changes in the organelles are underway.

Reviewer II: How do the keratin immunological profiles change with tobacco exposure? Are there changes in other keratin differentiation antigens?

Authors: This study was conducted to investigate the ultrastructural changes seen in the snuff-treated epithelium. To our knowledge nobody has reported the effects of American manufactured snuff exposure on the ultrastructure of the hamster cheek pouch. Immunological investigation has not yet been performed.

Reviewer II: What was the nature of the inflammatory

cell infiltrates? Are mitoses increased or abnormal with tobacco exposure?

Authors: They were mostly lymphocytes and some plasma cells and macrophages; mitoses were increased, but not significantly. No abnormal mitoses were seen.

Reviewer II: Do the authors believe that 2 years length of snuff exposure time is significant to determine the pathological effects of tobacco in this model?

Authors: In humans, snuff contact for 10 to 16 hours a day over a period of 20 years or more is required to produce oral cancer. In our study 2 years were not enough to produce oral cancer. Perhaps a prolonged contact with snuff (twice a day, 7 days a week) over a prolonged period is necessary to produce a malignant lesion in hamsters.

Reviewer II: What was the chemical composition of the snuff used in this experiment?

Authors: American manufactured snuff (Skoal), was used in this study. So far 3000 chemical constituents have been identified in the snuff (Robert DL, 1988, Natural tobacco flavor, Recent Adv Tobacco Sci. 14: 49-81).

Reviewer II: How do the results differ from the cited 6 month study?

Authors: Results over 24 months differ from 6 months exposure in term of (a) epithelium thickness, (6 months 34.23% and 24 months 60.50%); (b) a few desquamating

cells were seen in 6 months than 24 months; (c) honey-comb surface appearance was changed more in 24 months; (d) The number of membrane coating granules, keratohyalin granules and tonofilaments was increased in 24 months snuff exposed epithelium; and (e) the number of lymphocytes, plasma cells and macrophages was also increased.

P. Jungell: You assume that there may be a defect in the process whereby MCGs contents are extruded into intercellular spaces. On what finding do you base this assumption? Is it not possible that MCGs are increased in number in an attempt to enhance the permeability barrier?

Authors: Nicotine which is present in high levels in smokeless tobacco (snuff) increased the permeability of the epithelial barrier, [Reid HA, Kremer M, Chen YP and Squier CA, 1992. Effect of nicotine in oral carcinogenesis. J Dent Res 71: 142 (Abstract No. 294)]. This suggests that permeability barrier in snuff-treated epithelium is decreased. It could be related to our observation of increased number of MCGs, and majority of them are not extruding their contents into intercellular spaces to enhance the permeability barrier.